

Technical Note

Anterior Cruciate and Anterolateral Ligament Reconstruction Using Hamstring and Peroneus Longus Tendons: Surgical Technique Description

Diego Escudeiro de Oliveira, M.D., Victor Picchi Zaccharias, M.D.,
Melanie Mayumi Horita, M.D., Luiz Gabriel Betoni Guglielmetti, Ph.D.,
Aires Duarte Junior, M.D., and Pedro Baches Jorge, M.Sc.

Abstract: The main objective of this study is to describe a surgical technique that combines intra- and extra-articular techniques using the semitendinosus, gracilis, and peroneus longus to perform reconstruction of the anterior cruciate ligament and anterolateral ligament. This technique offers a more stable, fast, low-cost, and widely accessible procedure and consists of drilling 3 tunnels—1 femoral and 2 tibial tunnels—in which the grafts are fixed with interference screws. The fact that the peroneus longus graft is long and thick allows for robust reconstruction of the aforementioned ligaments.

An anterior cruciate ligament (ACL) tear is one of the most prevalent injuries resulting from sports trauma.^{1,2} Surgeons have long sought alternative techniques and grafts for ACL reconstruction (ACLR). Thus, concepts are changing, and new, safe graft options have emerged.³

Numerous studies have described the peroneus longus (PL) as a graft that has adequate biomechanical properties and is safe to use in ACLR without major biomechanical and kinematic repercussions for the foot and ankle from which it was harvested.^{4,5} Some studies have indicated high regeneration potential of the donor site after PL removal, which contributes to the selection of this type of graft.⁶

Another topic that is widely researched and is currently discussed is combined reconstruction of the anterolateral ligament (ALL) and ACL.⁷ Some

researchers have reported a higher degree of joint stability and a lower failure rate with the combined procedure than with isolated reconstruction of the ACL.⁸ It is estimated that only 10% of failures in primary ACLR are of traumatic origin⁹ and that the vast majority result from technical errors, loss of fixation, or underdiagnosed or neglected associated injuries. It is estimated that revision ACLR has worse outcomes and a higher failure rate than primary reconstruction.¹⁰ For this reason, many studies recommend that revision ACLR be performed using a combination of intra- and extra-articular reconstruction techniques, with the ALL providing a good option.¹¹

Surgical Technique

The procedure is performed with the patient in the supine position on the surgical table with the heels at the end of the table. The site to be approached is appropriately shaved using an electric shaver. A pneumatic tourniquet is placed proximally on both lower limbs and inflated after the placement of sterile drapes. The following anatomic points are identified with a surgical marking pen with 90° of knee flexion: patella, patellar tendon, proximal articular surface of the tibia, Gerdy tubercle, and fibular head.

Hamstring Tendon (Semitendinosus-Gracilis) Harvest

Harvest of the tendons of the semitendinosus and gracilis (STG) muscles is preferentially performed in the injured limb. For patients in whom these grafts were

From the Orthopedics and Traumatology Department, Faculdade de Ciências Médicas da Santa Casa de Misericórdia de São Paulo, São Paulo, Brazil.

The authors report no conflicts of interest in the authorship and publication of this article. Full ICMJE author disclosure forms are available for this article online, as [supplementary material](#).

Received July 27, 2020; accepted October 17, 2020.

Address correspondence to Diego Escudeiro de Oliveira, M.D., R. Dr. Cesário Mota Júnior, 61, Vila Buarque, São Paulo (SP), Brazil 01221-020. E-mail: diegoescudeiro@gmail.com

© 2020 by the Arthroscopy Association of North America. Published by Elsevier. This is an open access article under the CC BY-NC-ND license (<http://creativecommons.org/licenses/by-nc-nd/4.0/>).

2212-6287/201333

<https://doi.org/10.1016/j.eats.2020.10.030>

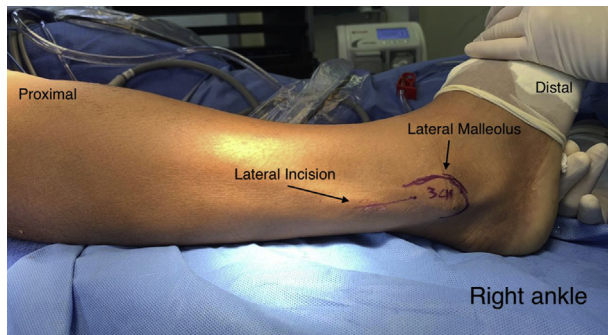


Fig 1. The right ankle is shown. The lateral malleolus and the incision site are traced. An incision in the skin is made 3 cm from the most distal point of the lateral malleolus.

used in the primary reconstruction, the grafts are harvested from the contralateral limb. First, a longitudinal incision of approximately 3 cm is made 4 cm distal to the knee joint. The fascia of the sartorius muscle and the tendons of the STG muscles are identified. A new transverse incision is made in the fascia of the sartorius muscle, and the STG is isolated. The STG is repaired with No. 1-0 Vicryl thread (Ethicon, Somerville, NJ), and its proximal insertions are removed with the aid of a tenotome.

PL Harvest

A single longitudinal incision of approximately 3 cm is made in the posterolateral region of the fibula over the PL (Fig 1). The incision is made in a distal-to-proximal direction, starting 3 cm proximal to the most distal point of the lateral malleolus, through the skin and subcutaneous tissue. After the subcutaneous tissue is separated, the PL is identified and isolated with the aid of a hemostatic forceps (mosquito or Kelly) after it is distinguished from the peroneus brevis (Fig 2). Both

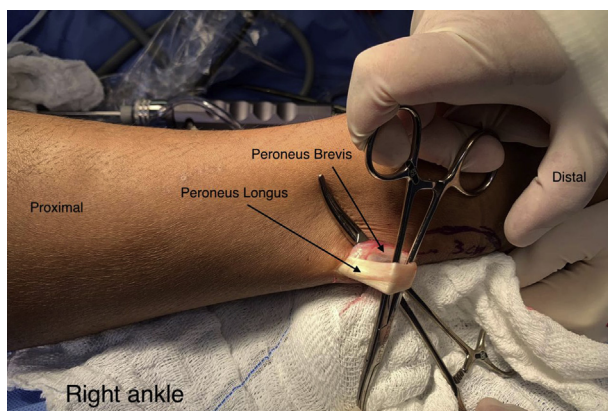


Fig 2. The right ankle is shown. A 3-cm incision is made proximal to the lateral malleolus. The peroneus longus and peroneus brevis tendons are identified and individualized.

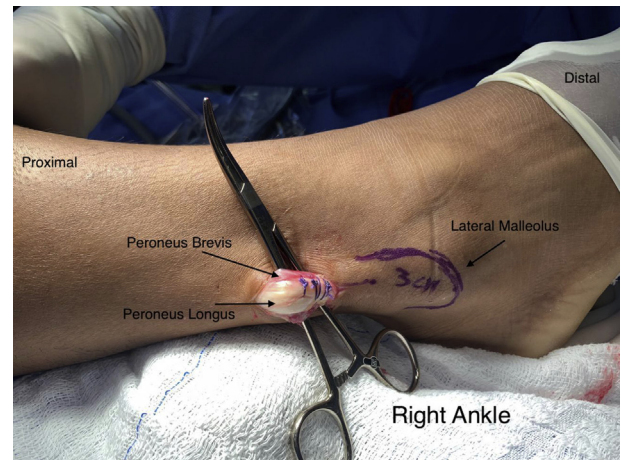


Fig 3. The right ankle is shown. Both peroneal tendons are brought together in the most distal region of the incision using single sutures with No. 1-0 Vicryl thread.

peroneal tendons are then brought together in the most distal region of the incision using single sutures with No. 1-0 Vicryl thread (Fig 3). After the tendons are unified with sutures, the PL is incised, repaired with No. 1-0 Vicryl thread (Fig 4), and removed to its proximal insertion with the aid of a tenotome, up to approximately 5 cm from the fibular head, avoiding any injury to the fibular nerve. The total length of the graft is approximately 24 cm.

Graft Preparation

The STG grafts are folded to form a single quadruple graft. Subsequently, the PL graft is incorporated into the STG grafts without folding, forming a quintuple graft in the most distal region and a single, more proximal graft comprising the remainder of the length of the PL, as shown in Figures 5 and 6.

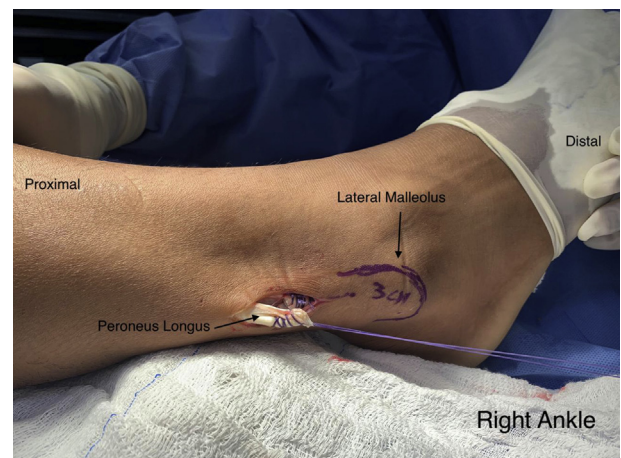


Fig 4. The right ankle is shown. After being combined with the peroneus brevis, the peroneus longus is incised and removed with the aid of a tenotome.

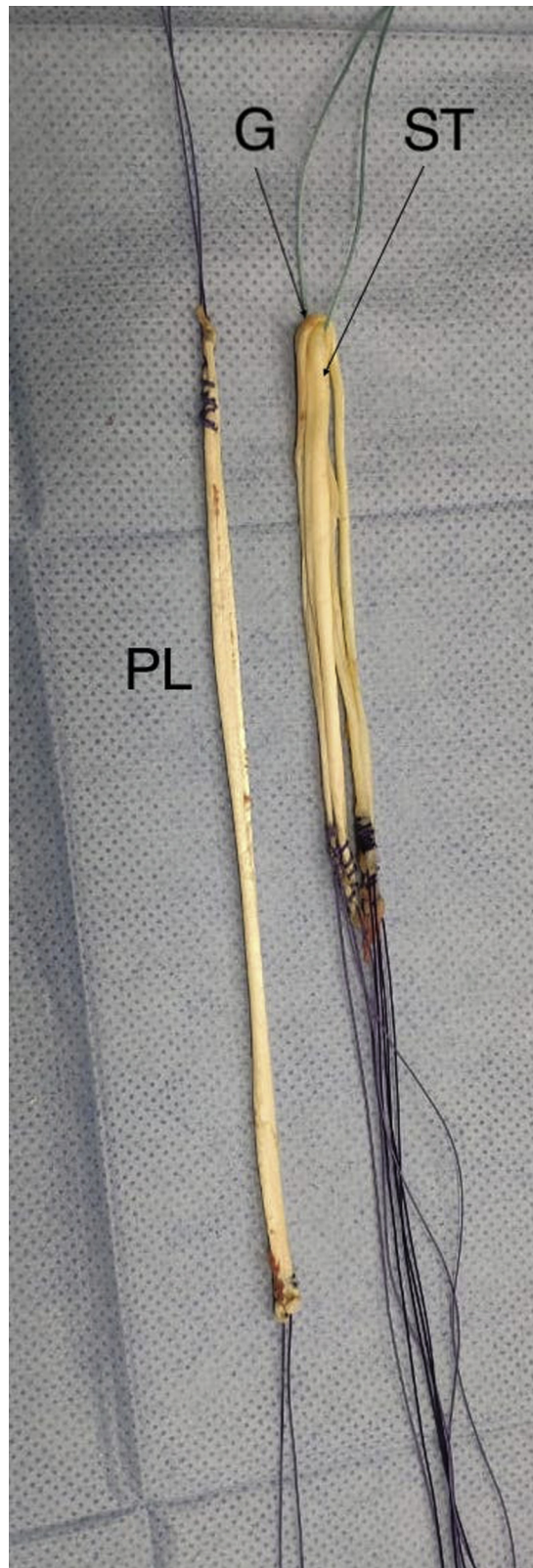

Fig 5. The grafts are shown: The hamstrings (gracilis [G] and semitendinosus [ST]) form a quadruple graft. (PL, peroneus longus.)

Arthroscopic Portals

Standardized anterolateral and anteromedial portals are used. We opt for a high anterolateral portal close to the patellar edge and flush with the patellar tendon. The anteromedial portal is created with care taken to form a good angle of inclination with the lateral intercondylar wall.

Arthroscopic Evaluation

We evaluate the central pivot ligaments and the associated lesions.

ACL Tunnels

Reconstruction is performed through anatomic positioning to create the femoral and tibial tunnels, and guides (Acuflex Pinpoint; Smith & Nephew, Andover, MA) are used to make the tunnels using the outside-in technique. The size of the tunnels is based on the diameter of the quintuple graft obtained.

ALL Tunnel

With the aid of radioscopy, the distance halfway between the Gerdy tubercle and the anterior eminence of the fibular head is found at approximately 1.5 cm from the articular surface. The skin is marked using a surgical pen before the procedure begins. At this point, a guidewire (Smith & Nephew) is passed through the tibia in the anterior direction, and a bone tunnel is constructed under radioscopic visualization (Fig 7).

Passage and Fixation

The graft is pulled through the femoral tunnel and passed through the tibial tunnel with the aid of a No. 5.0 Ethibond thread (Ethicon). The single portion of the graft is passed freely through the tibial and femoral tunnels until the quintuple graft portion occupies both tunnels. The graft is then pulled, and an interference screw (Biosure; Smith & Nephew) is fixed to the femur. The next step is to fix the inferior end of the quintuple graft to the tibia after pre-tensioning. Fixation is performed with the graft tensioned and the knee in total extension and after performance of the posterior drawer maneuver. After tibial fixation, the remaining PL is passed through the subcutaneous and ALL tunnels. The ligament is fixed under traction, mild valgus stress, and 30° of flexion (Fig 8, Video 1).

Discussion

ACLR is one of the most frequently performed surgical procedures in sports trauma.^{1,2} Despite numerous widely available studies, the treatment of such injuries can have a considerable complication rate and the traumatic rerupture rate is approximately 5% to 10%.⁹ As a result, researchers have sought possible causes of



Fig 6. The peroneus longus (PL) graft is incorporated into the hamstring grafts without folding, forming a quintuple graft in the most distal region and a single, more proximal graft comprising the remainder of the length of the PL. (G, gracilis; ST, semitendinosus.)

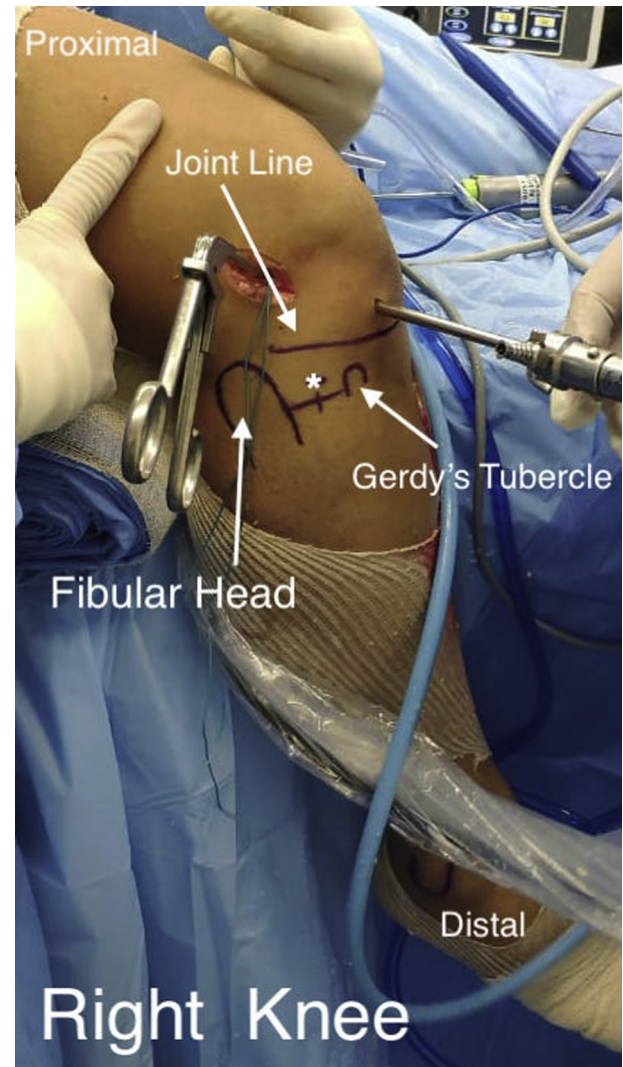
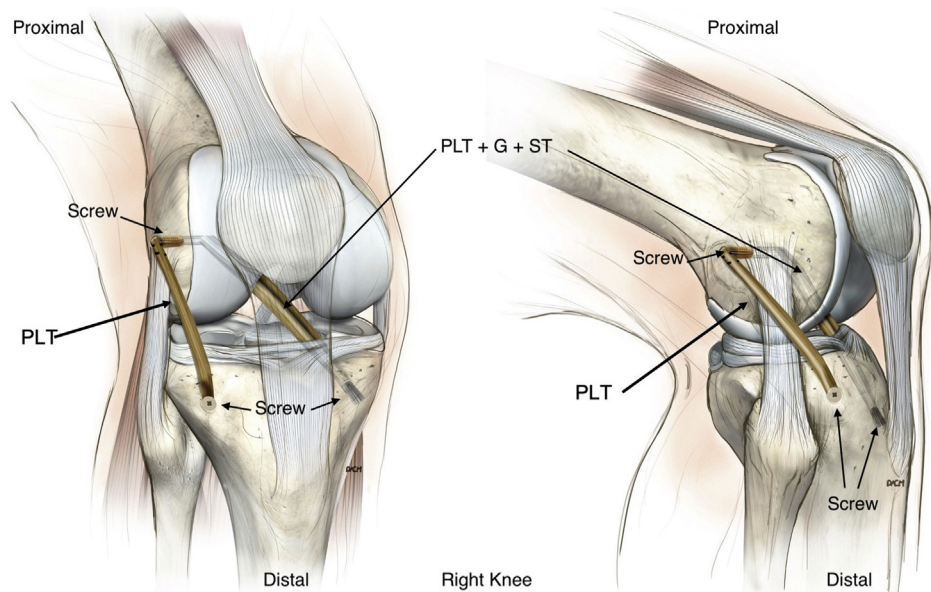


Fig 7. The right knee is shown. Anatomic landmarks are traced: fibular head, Gerdy tubercle, and articular line. A guidewire (Smith & Nephew) is passed halfway between the Gerdy tubercle and the fibular head through the tibia in the anterior direction, and a bone tunnel is constructed under radioscopic visualization. *Point where the tunnel to fix the ALL ligament will be performed.

the relatively high rate of failure and have pointed to the possible role of a state of articular hyperlaxity caused by residual rotational instability.^{8,9,11} Studies have shown that a high degree of initial instability, evidenced in the Lachman and pivot-shift tests, is strongly associated with the ACL rerupture rate.¹² Tanaka et al.¹³ cited residual rotational instability due to injury to the structures of the anterolateral compartment as a possible cause of high-grade pivot shift.

Some biomechanical studies have shown greater postoperative stability in patients who undergo combined ACL-ALL reconstruction than in those who

Fig 8. To fix the grafts, we perform the following sequence: The single portion of the graft is passed freely through the tibial and femoral tunnels until the quintuple portion occupies both tunnels. Then, the graft is pulled, and an interference screw is fixed to the femur. The next step is to fix the lower end of the quintuple graft to the tibia after pre-tensioning. Fixation is performed with the graft tensioned and the knee in full extension and after performing the posterior drawer maneuver. After tibial fixation, the remaining peroneus longus is passed through the subcutaneous and ALL tunnels. The ligament is fixed under traction, mild valgus stress, and 30° of flexion. (PLT, peroneus longus tendon; DCM, designer's signature; G, gracilis; ST, semitendinosus.)



undergo isolated ACLR.¹⁴ Other studies that have specifically evaluated the revision ACLR procedure with or without ALL reconstruction indicated a lower persistence of instability and greater return to activities at the same preoperative level in patients who underwent the combined procedure.¹⁵ Given the recommendations of these studies, we chose to perform an ACLR procedure that includes both intra- and extra-articular reconstruction and is minimally invasive and widely available.

The use of the PL for ACLR has been described by several studies and seems to be a good and safe graft option.¹⁶ Rhatomy et al.¹⁷ published a prospective cohort study (Level II evidence) showing excellent functional results with donor-site morbidity similar to that using the STG. Other studies concluded that the removal of the PL does not cause gait change or ankle instability.^{4,5,18}

In a case series of 31 patients in whom the American Orthopaedic Foot & Ankle Society (AOFAS) and Foot & Ankle Disability Index (FADI) scores, ankle eversion,

and first-ray plantar flexion strength were evaluated, at 6 months after harvest of the PL, no significant difference was found between the operated limb and the contralateral limb.¹⁹ Another prospective study that evaluated the use of the PL tendon for posterior cruciate ligament reconstruction concluded that after a 2-year follow-up period, the patients maintained excellent single- and triple-hop test and ankle function results.²⁰

Currently, some countries are experiencing difficulties with revision ACLR because homologous grafts are not widely available. This often complicates the extra-articular reconstruction procedure combined with ACL revision.

The use of a graft that is easy to harvest with minimal invasiveness, is associated with few complications at the donor site, and, in particular, has a good diameter and length definitively makes intra- and extra-articular reconstruction of the ACL accessible to all surgeons. The described procedure is technically simple and reproducible and can be easily performed to obtain greater stability and success in ACLR (Tables 1 and 2).

Table 1. Advantages and Disadvantages of Procedure

Advantages

- The PL removal technique is not complicated.
- The availability of the PL graft is greater than that of allograft.
- There is no considerable increase in surgical time.

Disadvantages

- It is necessary to use 1 additional fixation device.
- There is a need to remove the graft from another site.
- One additional incision is made in the lateral region of the tibia.
- The patient is exposed to minimal radiation.

PL, peroneus longus.

Table 2. Pearls and Pitfalls

The PL must be properly sutured to the PB during graft removal. The ALL graft must pass superficially to the fibular collateral ligament. It is important to fix the ALL under moderate valgus stress and 30° of flexion.

ALL, anterolateral ligament; PB, peroneus brevis; PL, peroneus longus.

References

1. Gianotti SM, Marshall SW, Hume PA, Bunt L. Incidence of anterior cruciate ligament injury and other knee ligament injuries: A national population-based study. *J Sci Med Sport* 2009;12:622-627.
2. Guimarães MV, Junior LH, Terra DL. Reconstruction of the anterior cruciate ligament with the central third of the quadriceps muscle tendon: Analysis of 10-year results. *Rev Bras Ortop* 2015;44:306-312.
3. Diermeier T, Tisherman R, Hughes J, et al. Quadriceps tendon anterior cruciate ligament reconstruction. *Knee Surg Sports Traumatol Arthrosc* 2020;28:2644-2656.
4. Pearsall AWIV, Hollis JM, Russell GV Jr, Scheer Z. A biomechanical comparison of three lower extremity tendons for ligamentous reconstruction about the knee. *Arthroscopy* 2003;19:1091-1096.
5. Shi FD, Hess DE, Zuo JZ, et al. Peroneus longus tendon autograft is a safe and effective alternative for anterior cruciate ligament reconstruction. *J Knee Surg* 2019;32:804-811.
6. Kerimoğlu S, Aynaci O, Saraçoğlu M, Aydın H, Turhan AU. Peroneus longus tendon ile ön çapraz bağ rekonstrüksiyonu [Anterior cruciate ligament reconstruction with the peroneus longus tendon]. *Acta Orthop Traumatol Turc* 2008;42:38-43 [in Turkish].
7. Helito CP, do Amaral C, Camargo DB, Bonadio MB, Pecora JR, Demange MK. Extra-Articular reconstruction associated with the anterior cruciate ligament in Brazil. *Acta Ortop Bras* 2019;27:202-206.
8. Helito CP, Sobrado MF, Giglio PN, et al. Combined reconstruction of the anterolateral ligament in patients with anterior cruciate ligament injury and ligamentous hyperlaxity leads to better clinical stability and a lower failure rate than isolated anterior cruciate ligament reconstruction. *Arthroscopy* 2019;35:2648-2654.
9. George MS, Dunn WR, Spindler KP. Current concepts review: Revision anterior cruciate ligament reconstruction. *Am J Sports Med* 2006;34:2026-2037.
10. Wright RW, Gill CS, Chen L, et al. Outcome of revision anterior cruciate ligament reconstruction: A systematic review. *J Bone Joint Surg Am* 2012;94:531-536.
11. Louis ML, D'ingrado P, Ehkirch FP, et al. Combined intra- and extra-articular grafting for revision ACL reconstruction: A multicentre study by the French Arthroscopy Society (SFA). *Orthop Traumatol Surg Res* 2017;103:S223-S229 (suppl).
12. Magnussen RA, Reinke EK, Huston LJ, et al. Effect of high-grade preoperative knee laxity on 6-year anterior cruciate ligament reconstruction outcomes. *Am J Sports Med* 2018;46:2865-2872.
13. Tanaka M, Vyas D, Moloney G, Bedi A, Pearle AD, Musahl V. What does it take to have a high-grade pivot shift? *Knee Surg Sports Traumatol Arthrosc* 2012;20:737-742.
14. Rasmussen MT, Nitri M, Williams BT, et al. An in vitro robotic assessment of the anterolateral ligament, part 1: Secondary role of the anterolateral ligament in the setting of an anterior cruciate ligament injury. *Am J Sports Med* 2016;44:585-592.
15. Lee DW, Kim JG, Cho SI, Kim DH. Clinical outcomes of isolated revision anterior cruciate ligament reconstruction or in combination with anatomic anterolateral ligament reconstruction. *Am J Sports Med* 2019;47:324-333.
16. Song X, Li Q, Wu Z, Xu Q, Chen D, Jiang Q. Predicting the graft diameter of the peroneus longus tendon for anterior cruciate ligament reconstruction. *Medicine (Baltimore)* 2018;97:e12672.
17. Rhatomy S, Asikin AIZ, Wardani AE, Rukmoyo T, Lumban-Gaol I, Budhiparama NC. Peroneus longus autograft can be recommended as a superior graft to hamstring tendon in single-bundle ACL reconstruction. *Knee Surg Sports Traumatol Arthrosc* 2019;27:3552-3559.
18. Nazem K, Barzegar M, Hosseini A, Karimi M. Can we use peroneus longus in addition to hamstring tendons for anterior cruciate ligament reconstruction? *Adv Biomed Res* 2014;3:115.
19. Rhatomy S, Wicaksono FH, Soekarno NR, Setyawan R, Primasara S, Budhiparama NC. Eversion and first ray plantarflexion muscle strength in anterior cruciate ligament reconstruction using a peroneus longus tendon graft. *Orthop J Sports Med* 2019;7. 2325967119872462.
20. Setyawan R, Soekarno NR, Asikin AIZ, Rhatomy S. Posterior cruciate ligament reconstruction with peroneus longus tendon graft: 2-Years follow-up. *Ann Med Surg (Lond)* 2019;43:38-43.